

American Society of Interventional Pain Physicians®
Society of Interventional Pain Management Surgery Centers Inc.
"The Voice of Interventional Pain Management"

81 Lakeview Drive, Paducah, KY 42001
Phone: (270) 554-9412 - Fax: (270) 554-5394
www.asipp.org; www.sipms.org

September 15, 2021

Noridian Healthcare Solutions, LLC JE Part B Contractor Medical Director(s)
Attention: Draft LCD Comments
PO Box 6781
Fargo, ND 58108-6781
policydraft@noridian.com

RE: Proposed Local Coverage Determination (LCD): Epidural Procedures for Pain Management (DL39093)

On behalf of the California, Hawaii, and Nevada Societies of Interventional Pain Physicians, the American Society of Interventional Pain Physicians (ASIPP), and the Society of Interventional Pain Management Surgery Centers (SIPMS), we would like to thank you for publishing the proposed LCD for epidural procedures for pain management in multiple jurisdictions with the same document. We appreciate all your hard work, multijurisdictional committee meetings, and extensive review of the literature.

The proposed policy requires significant revisions and amendments in four (4) important areas:

1. Inclusion of percutaneous adhesiolysis, which has been discussed in multijurisdictional committee with a score of 3.21. In addition, appropriate literature analysis based on relevant randomized controlled trials (RCTs) (1-11), systematic reviews and guidelines (12-17) shows Level I to Level II evidence with strong to moderate recommendation (17).
2. Please revise the coverage indications with the replacement of radiculopathy with radicular pain and limiting these indications for transforaminal epidural injections with addition of disc herniation to present indications. In addition, the covered indications must include degenerative disc disease, spinal stenosis, post surgery syndrome, and discogenic pain without evidence of facet joint or sacroiliac joint pain as they have been covered in the previous LCDs with an abundance of evidence (17-52).

The evidence for multiple degenerative conditions and discogenic pain without facet joint or sacroiliac joint pain has been presented in multiple randomized controlled trials, systematic reviews, and guidelines with a multijurisdictional committee score of 3.43 (17,18,22,32,41,44,47,50).

3. Please revise procedural limitations and outcomes assessment in reference to the duration of relief, with expansion, similar to the previous LCD, with 2 procedures in the diagnostic or initial phase with 4 and 6 weeks apart after first and second procedures per spinal region, followed by 4 epidural injections per spinal region in a rolling year, initiated with a third procedure. If the patients' condition includes an acute lumbar herniated nucleus pulposus, then the patient should wait no longer than 2 weeks for the first epidural steroid injection and no longer than 2 weeks for a second and or third epidural steroid injection, if indicated. Additionally, to provide a second epidural after 3 months of sustained 50% pain relief is not supported by the literature. An overwhelming evidence in the literature shows the first

procedure providing 5.69 ± 8.23 in 1,510 patients assessed and the second procedure providing 10.02 ± 12.57 weeks assessed in 1,402 patients (40-52). In addition, multiple other studies, including the study by Friedly et al (53), also shows 6 weeks of relief rather than 3 months of relief.

4. Coverage for multiple procedures in separate regions in the same session when reasonable and necessary.

BACKGROUND

ASIPP is a not-for-profit professional organization founded in 1998 now comprising over 4,500 interventional pain physicians and other practitioners who are dedicated to ensuring safe, appropriate, and equal access to essential pain management services for patients across the country suffering with chronic and acute pain. There are approximately 8,500 appropriately trained and qualified physicians practicing interventional pain management in the United States. ASIPP is comprised of 50 affiliated state societies, and the Puerto Rico Society of Interventional Pain Physicians.

Interventional pain management is defined as the discipline of medicine devoted to the diagnosis and treatment of pain related disorders principally with the application of interventional techniques in managing sub acute, chronic, persistent, and intractable pain, independently or in conjunction with other modalities of treatment (54).

Interventional pain management techniques are minimally invasive procedures including, percutaneous precision needle placement, with placement of drugs in targeted areas or ablation of targeted nerves; and some surgical techniques such as laser or endoscopic discectomy, intrathecal infusion pumps and spinal cord stimulators, for the diagnosis and management of chronic, persistent or intractable pain (55).

SIPMS is a not-for-profit professional organization founded in 2005, with membership involving surgical centers focusing on interventional pain management, dedicated to ensuring safe, appropriate, and equal access to essential pain management services for patients across the country suffering with chronic pain. There are approximately 500 surgery centers across the nation approved by Medicare providing solely, or an overwhelming majority, of interventional pain management services.

Medicare

Based on the 21st Century Cures Act of 2016, the LCD process is updated to provide greater transparency, consistency, and patient engagement.

Medicare covers medically reasonable and necessary services. If the service is:

- Safe and effective;
- Not experimental or investigational; and
- Appropriate, including the duration and frequency in terms of whether the service or item is:
 - Furnished in accordance with accepted standards of medical practice for the diagnosis or treatment of the beneficiary's condition or to improve the function of a malformed body member;
 - Furnished in a setting appropriate to the beneficiary's medical needs and condition;
 - Ordered and furnished by qualified personnel

Further, LCD development process must assure beneficiary access to care.

The National Contractor Advisory meeting consisting of national experts, geographic representation, academic and clinical practice, various specialties that perform are involved in the procedure, have performed evidence-based review. American Society of Interventional Pain Physicians through its multiple

CAC members and subject matter experts, have participated in National Contractor Advisory Committee meeting for policy development. Based on the hierarchy of evidence review, an overwhelming majority of the procedures received recommendations based on randomized controlled trials, appropriately performed systematic reviews and meta-analysis, and evidence-based clinical practice guidelines, rather than consensus based guidance.

DISCUSSION OF THE ISSUES

PERCUTANEOUS ADHESIOLYSIS

There was an LCD request for percutaneous adhesiolysis at CGS. Subsequently, it was incorporated into multijurisdictional committee assessment as an epidural intervention. Percutaneous adhesiolysis is an epidural intervention, which differs from epidural injections with additional involvement of catheter-based adhesiolysis. It fits the criteria of the epidural intervention as described in evidence-based guidelines (17). Based on multiple moderate to high-quality RCTs and systematic reviews (1-17), the evidence was shown to be Level I with strong recommendation in evidence-based guidelines (17) for long-term improvement of post lumbar surgery syndrome after failure of conservative management and fluoroscopically-guided epidural injections. The evidence for lumbar central spinal stenosis based on relevant, moderate to high-quality RCTs, observational studies, and systematic reviews was Level II with moderate to strong recommendation in patients nonresponsive to conservative management and fluoroscopically guided epidural injections. The evidence was Level II with moderate to strong recommendation for long-term improvement in patients nonresponsive to conservative management and fluoroscopically guided epidural injections with one high-quality, placebo-controlled RCT and multiple large scale observational studies for recalcitrant disc herniation in patients (5,15,56-60). To summarize, epidural adhesiolysis has been studied in multiple randomized controlled trials (1-11) and multiple systematic reviews and meta-analyses have been performed (12-17). Of 5 available systematic reviews, one showed negative results and all others showed positive results in post lumbar surgery syndrome, central spinal stenosis, and refractory disc herniation.

Further, subject matter experts and Carrier Advisory Committee (CAC) member survey of the multijurisdictional committee scored 3.21 on a scale of 1 to 5.

Lack of addition to this procedure will be significantly consequential. As of now, Palmetto and Noridian have issued non-coverage determinations (NCDs). In other jurisdictions, this procedure is offered; however, with the publication of epidural policy it may encourage other jurisdictions to do the same. Now which is a differential decline in access will become a universal decline in access. In addition, percutaneous adhesiolysis procedure, which is performed only after failure of fluoroscopically directed epidural injections, may reduce other expensive modalities including repeat surgical interventions, spinal cord stimulation, intrathecal infusion systems, and increased opioid prescriptions. The cost utility analysis have shown similar cost utility compared to other modalities. This may also lead to utilization and continuation of transforaminal epidural injections, which cost the same to Medicare or less with approval of percutaneous adhesiolysis.

Based on Medicare Integrity Manual, Chapter 13, Section 13.5.4, Reasonable and Necessary Criteria to be Included in an LCD, are met. In addition, it is crucial to retain this procedure as one of the hallmarks of LCD development process is: “assuring beneficiary access to care.”

COVERED INDICATIONS

The policy states the following:

- “• **Lumbar, cervical, or thoracic radiculopathy and/or neurogenic claudication due to central disc herniation, osteophyte or osteophyte complexes, severe degenerative disc disease, producing foraminal or central stenosis⁵ OR**
- **Post laminectomy syndrome,^{6,7,8} OR**
- **Acute herpes zoster associated pain.⁶**

AND

- **Radicular pain is severe enough to cause a significant degree of functional disability or vocational disability measured at baseline using an objective pain scale*. A functional assessment scale must be performed at baseline if function is considered as part of the assessment.**

AND

- **Pain duration of at least four (4) weeks, and the inability to tolerate noninvasive conservative care or medical documentation of failure to respond to four (4) weeks of noninvasive conservative care or acute herpes zoster refractory to conservative management where a four (4) week wait is not required.⁹”**

These indications may be appropriate for transforaminal epidural injections with appropriate language revisions to radicular pain. However, the indications for interlaminar and caudal epidural injections should be expanded.

Radiculopathy should be replaced with radicular pain. Often these terms are used interchangeably. All types of procedures have been shown to be effective in managing radicular pain, even though the evidence is somewhat better for transforaminal epidural injections and transforaminal epidural injections are indicated only when there is radicular pain. However, there is no evidence of any of the procedures in managing radiculopathy.

As you know, most patients with severe radicular pain do not have physical examination or imaging abnormalities. Neurological deficits are not common and are not necessary to support a diagnosis of radicular pain. In addition, the specificity and sensitivity of neurological examination with straight leg raising and motor dysfunction are nonspecific. Imaging findings also may be variable with or without mechanical nerve compression.

Consequently, we request that this be revised as follows:

History and/or physical examination, and diagnostic imaging supporting one of the following: lumbar, cervical, or thoracic radicular pain.

We request the addition of disc herniation and degenerative disc disease as causative factors.

While all types of procedures may be performed; however, for transforaminal epidural injections, these indications must be limited. Further, for interlaminar and caudal epidural injections, the indications should be expanded as covered previously with degenerative disc disease, disc herniation, spinal stenosis without neurogenic claudication or radicular pain, and discogenic pain without facet joint or sacroiliac joint pain.

The literature on disc herniation is extensive similar to the radicular pain as shown above (45,46,49,61-79).

Degenerative disc disease without radicular pain is common and has been treated with epidural injections over the years. It is difficult to isolate these patients from others in various studies published. However, these have been covered in previous LCDs, even the present LCD shows some of the indications. Post surgery syndrome may also present without radicular pain and may not have facet joint or sacroiliac joint pain.

Discogenic pain without facet joint or sacroiliac joint pain has been shown to be well managed with epidural injections (17,18,21,31,41,44,47,50). Clinical and cost utility analysis show similar effectiveness as in disc herniation or spinal stenosis or post lumbar surgery syndrome. Consequently, degenerative disc disease without radicular pain, spinal stenosis without neurogenic claudication, post surgery syndrome without radicular pain, and discogenic pain without facet joint or sacroiliac joint pain must be covered. Failure to do so will leave majority of the patients without any further treatment (80-83). Based on facet joint policy, patients not achieving 80% relief on 2 consecutive comparative local anesthetic blocks will be judged as negative for facet joint pain and will be positive and responsive to interlaminar or caudal epidural injections, as shown in the literature, systematic reviews and guidelines, with a multijurisdictional committee score of 3.43 (17,18,21,31,41,44,47,50).

Pain duration of at least 4 weeks and the inability to tolerate non-invasive conservative care or medical documentation of failure to respond to 4 weeks of non-invasive conservative care should be eliminated for acute radicular pain, similar to acute herpes zoster. Acute radicular pain and acute herpes zoster may be treated after 1-2 weeks of non-invasive conservative care.

Under covered indications #4: Caudal epidural steroid injections (CESI) and interlaminar epidural steroid injections involving a maximum of one level are considered medically reasonable and necessary.

We request this to be revised to caudal epidural injections and interlaminar epidural injections involving a maximum of one level per region are considered medically reasonable and necessary.

Under covered indications #6, this has been discussed above in reference to the relief.

Under covered indications #7 which describes ESIs injectants must include corticosteroids, anesthetics, anti-inflammatories, and/or contrast agents.

Please reword this as: Epidural injectates must include either corticosteroids, anesthetics, anti-inflammatories, or contrast agents or combination thereof.

This will avoid the confusion in reference to that corticosteroids are mandated.

We request that approved codes should be revised with addition of degenerative disc disease codes and disc herniation codes as follows:

Further, approved codes do not include degenerative disc disease and disc herniation. Consequently, please add the following:

- M50.21 Other cervical disc displacement, high cervical region
- M50.221 Other cervical disc displacement at C4-C5 level
- M50.222 Other cervical disc displacement at C5-C6 level
- M50.223 Other cervical disc displacement at C6-C7 level
- M50.23 Other cervical disc displacement, cervicothoracic region
- M50.31 Other cervical disc degeneration, high cervical region
- M50.321 Other cervical disc degeneration at C4-C5 level

M50.322 Other cervical disc degeneration at C5-C6 level
M50.323 Other cervical disc degeneration at C6-C7 level
M50.33 Other cervical disc degeneration, cervicothoracic region

M51.24 Other intervertebral disc displacement, thoracic region
M51.25 Other intervertebral disc displacement, thoracolumbar region
M51.34 Other thoracic disc degeneration, thoracic region
M51.35 Other thoracic disc degeneration, thoracolumbar region

M51.26 Other intervertebral disc displacement, lumbar region
M51.27 Other intervertebral disc displacement, lumbosacral region
M51.36 Other intervertebral disc degeneration, lumbar region
M51.37 Other intervertebral disc degeneration, lumbosacral region

PROCEDURAL LIMITATIONS AND OUTCOMES ASSESSMENT

Outcomes Assessment

The policy at present limits the second procedure based on 50% improvement for 3 months, which is non-achievable and non-evidence based statement. As we have described, analysis of 13 randomized controlled trials (40-52) with inclusion of 1,510 patients showed the relief following first procedure of 5.69 ± 8.23 weeks. The same studies also showed the relief after the second procedure of 10.02 ± 12.57 weeks with inclusion of 1,402 patients, as shown in attached Tables 1, 2, and 3. This assessment was carried out for 2-year period, except in one study where it was limited to one-year. Further, study by Friedly et al (53) also showed less than 6 weeks of relief with one injection.

These criteria in conjunction with covered indications will eliminate majority of the patients receiving epidural injections. This may range as high as 90%. This will create a major access issue and various issues related to opioid epidemic and explosion of more expensive procedures.

Consequently, we request you replace this language as follows with expansion, similar to the previous LCDs:

With 2 epidural injections in the diagnostic or initial phase with 4 and 6 weeks apart after first and second procedures per spinal region, followed by 4 epidural injections per spinal region in a rolling year, initiated with a third procedure.

Under Limitations #5, ESIs to treat non-specific low back pain (LBP), axial spine pain, complex regional pain syndrome, widespread diffuse pain, pain from neuropathy from other causes, cervicogenic headaches are considered investigational and therefore are not considered medically reasonable and necessary.

As we have discussed above, please revise this limitation to epidural injections to treat non-specific low back pain, widespread diffuse pain, are considered investigational and therefore are not considered medically reasonable and necessary.

As described earlier, axial spine pain without facet joint or sacroiliac joint pain, complex regional pain syndrome, neuropathy from other causes, and cervicogenic headaches are responsive to epidural injections. These are performed in a minority of cases. There is no reason to restrict patient access in these areas.

Under Limitations #12, steroid dosing should be the lowest effective amount and not to exceed 40mg for methyl prednisone, 10-20mg for triamcinolone acetate, and 10mg (10mg/mL) for dexamethasone phosphate per session.

These doses may not be accurate. Further, the described dosages in multijurisdictional committee and extensive literature are different.

Consequently, we request this section to be changed as follows:

Steroid dosing should be the lowest effective amount and not to exceed 80 mg of triamcinolone, 80 mg of methylprednisolone, 12 mg of betamethasone, and 16 mg of dexamethasone per session.

Under Limitations #13, this limitation must be removed. This is not appropriate as discussed above.

Under Definitions, some policies state transforaminal epidural steroid injections (TFESI) are defined as “...placing the needle in the posterior-superior quadrant of the intervertebral foramen (neuroforamen) to inject near the dorsal root ganglion and exiting spinal nerve root (previously known as a selective nerve root block).”

This definition, as well as procedural guidance, creates unnecessary risk, increases intravascular injection of local anesthetic or steroid, and may even make CMS a party to malpractice suits as it will be described as policy decision.

Lumbar transforaminal epidural injections are considered as risky procedures. However, cervical and thoracic transforaminal epidural injections are associated with extreme risk. There have been almost 500 cases of tragic paralysis cases over the years. The safety considerations include not only avoiding injury to the nerve root as described in the procedure, but more importantly, avoiding the trauma to the arteries and, finally, most importantly, injecting particulate or non-particulate agents into a blood vessel. All the risks have been attributed to particulate agent. However, non-particulate agents also can cause trauma with spasms or release of a thrombus, resulting in spinal cord infarction, though rare (84).

For lumbar region, Murthy et al (85) showed that 95% of the radiculomedullary arteries are located in the superior one-half of the neural foramen as opposed to only 9% and 2% for mid and anterior third, respectively, as shown in Fig. 1.

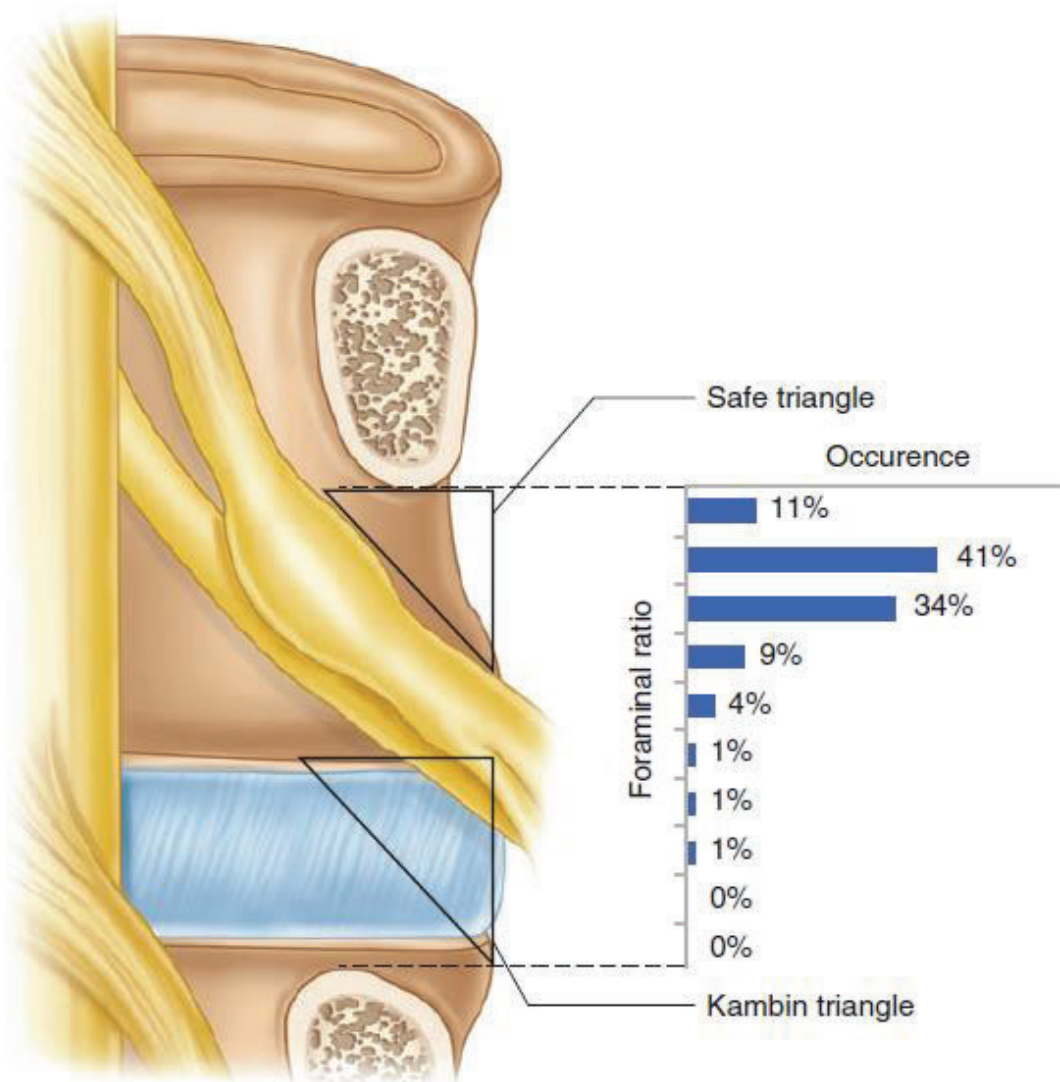


Fig. 1. Location of radicular medullary arteries, as determined at the mid-pedicular plane, is graphically depicted using the foraminal ratio, in 0.10 increments

Adapted from Murthy et al (85).

In addition, it was also shown that the radicular artery follows the cranial aspect of the spinal nerves, which reside in the large upper part of the foramen as described in the policy (86). The so-called description of safe triangle as is shown in the policy, only provides safety of not penetrating the nerve root, whereas it tremendously increases the penetration of the artery. Consequently, multiple other approaches have been described, including infraneural approaches, whereas the approach in the policy is known as supraneural. Subsequently, other names are also utilized calling Kambin Triangle approach, etc.

The same philosophy may be applied for cervical and thoracic epidural injections with infraneural approach. However, these procedures are considered extremely risky in both thoracic and cervical spine. Consequently, we request that any type of procedural language be removed or just simply state that “placing a needle in the intervertebral foramen.”

MULTIPLE TREATMENTS

The policy states no multiple treatments can be performed. We can understand that in a single region there may not be multiple procedures; however, when these are performed in different regions there is no basis for this. In general, literature shows that 60% of the patients with spinal pain have more than one region involved. Consequently, this will significantly restrict the access. It also causes patient inconvenience, provider increased workload and costs, and finally it is more expensive to the program with payment of 200% instead of 150%.

Unintended consequence of this will include Medicare Advantage Plans going to the same with high copays and deductibles doubling the pain.

Further, all government plans, Medicaid, commercial payers also follow this. Apart from expense, it will result in significant lack of access, with expenses, family involvement with transportation, and multiple COVID tests. In addition, we also have concerns with regards to long-term treatment and restrictions.

Treatments Exceeding 12 Months

This limitation is unreasonable and the requirements add significant documentation burden, and also affects the access. The LCD already has sufficient guardrails in place to prevent overuse or abuse of the procedure while outlining appropriate use and thus we request that this limitation #13 that limits epidurals to 12 months be removed.

As long as a physician documents medical necessity as described in the LCD with appropriate improvement, that should suffice.

Other Issues Contrast

Contrast injection may be reworded with except for patients who have a documented contrast allergy or are pregnant.

Epidural Steroid Nomenclature

The policy calls for epidural steroid injections; however, if epidurals do not include steroids, they are not epidural steroid injections and the language may be changed to epidural procedure or epidural injection.

Conservative Management

While some patients benefit from multimodal treatments, others who experience relief from epidural injections may not require additional conservative management, except for structured exercise program.

Consequently, the language may be changed allowing for epidural procedures to be performed in conjunction with conservative treatments.

Summary and References

There are a multitude of errors in the references. Even though summary is extensive, it does not include appropriate references. It will be too extensive to include. If you need further assistance on these issues, we will be happy to provide you with the appropriate positioning of the references.

CONCLUSION

To summarize, failure to provide appropriate care to these patients will lead to more expensive treatments and hinder the access and may fuel opioid epidemic in addition to explosion of modalities such as spinal cord stimulation, intrathecal infusion system implantables, PILD procedure, interspinous prosthesis implants, and finally surgical interventions. In addition to this, it will increase the expenses to the program as described earlier and also reduce the access significantly, not only to Medicare patients, but also

Medicare Advantage, all governmental programs, Medicaid, and finally commercial insurers. It will cause substantial inconvenience to the patients with multiple copays, difficulties with drivers bringing them to the procedures, and multiple COVID tests. In essence, this policy will hurt the most vulnerable, namely the elderly, economically disadvantaged, and minority population which is quite opposite the goals of Medicare program.

In reference to the inclusion criteria, it will be cost effective to utilize clinically effective modalities while maintaining the access and without fueling the opioid epidemic and increasing health care costs exponentially.

Criteria should also increase appropriate diagnosis for treatment of complex regional pain syndrome (CRPS), cervicogenic headache, and neuropathic pain. The expenditures for Medicare will be similar whether these patients are treated with epidurals or sympathetic blocks.

Thank you again for all your dedication. We hope these comments will be helpful in revising the LCD, which will be acceptable to all involved, which will not only improve the patient care, but within the parameters of Chapter 13 of Medicare Program Integrity Manual and Medicare's promise to provide appropriate care to elderly.

ASIPP, SIPMS, AND STATE SOCIETIES

REFERENCES

1. Manchikanti L, Cash KA, McManus CD, Pampati V, Singh V, Benyamin R. The preliminary results of a comparative effectiveness evaluation of adhesiolysis and caudal epidural injections in managing chronic low back pain secondary to spinal stenosis: A randomized, equivalence controlled trial. *Pain Physician* 2009; 12:E341-E354.
2. Manchikanti L, Cash KA, McManus CD, Pampati V. Assessment of effectiveness of percutaneous adhesiolysis in managing chronic low back pain secondary to lumbar central spinal canal stenosis. *Int J Med Sci* 2013; 10:50-59.
3. Manchikanti L, Singh V, Cash KA, Pampati V, Datta S. A comparative effectiveness evaluation of percutaneous adhesiolysis and epidural steroid injections in managing lumbar post-surgery syndrome: A randomized, equivalence controlled trial. *Pain Physician* 2009; 12:E355-E368.
4. Manchikanti L, Singh V, Cash KA, Pampati V, Datta S. Assessment of effectiveness of percutaneous adhesiolysis and caudal epidural injections in managing lumbar post-surgery syndrome: A 2-year follow-up of randomized, controlled trial. *J Pain Res* 2012; 5:597-608.
5. Gerdsmeyer L, Wagenpfeil S, Birkenmaier C, et al. Percutaneous epidural lysis of adhesions in chronic lumbar radicular pain: A randomized, double-blind, placebo-controlled trial. *Pain Physician* 2013; 16:185-196.
6. Chun-jing H, Hao-xiong N, Jia-xiang N. The application of percutaneous lysis of epidural adhesions in patients with failed back surgery syndrome. *Acta Cir Bras* 2012; 27:357-362.
7. Manchikanti L, Rivera JJ, Pampati V, et al. One-day lumbar epidural adhesiolysis and hypertonic saline neurolysis in treatment of chronic low back pain: A randomized, double-blind trial. *Pain Physician* 2004; 7:177-186.
8. Veihelmann A, Devens C, Trouillier H, Birkenmaier C, Gerdsmeyer L, Refior HJ. Epidural neuroplasty versus physiotherapy to relieve pain in patients with sciatica: A prospective randomized blinded clinical trial. *J Orthop Sci* 2006; 11:365-369.
9. Akbas M, Elawamy AR, Salem HH, Fouad AZ, Abbas NA, Dagistan G. Comparison of 3 approaches to percutaneous epidural adhesiolysis and neuroplasty in post lumbar surgery syndrome. *Pain Physician* 2018; 21:E501-E508.
10. Heavner JE, Racz GB, Raj P. Percutaneous epidural neuroplasty: Prospective evaluation of 0.9% NaCl versus 10% NaCl with or without hyaluronidase. *Reg Anesth Pain Med* 1999; 24:202-207.

11. Karm MH, Choi SS, Kim DH, et al. Percutaneous epidural adhesiolysis using inflatable balloon catheter and balloon-less catheter in central lumbar spinal stenosis with neurogenic claudication: A randomized controlled trial. *Pain Physician* 2018; 21:593-606.
12. Manchikanti L, Knezevic NN, Sanapati SP, Sanapati MR, Kaye AD, Hirsch JA. Is percutaneous adhesiolysis effective in managing chronic low back and lower extremity pain in post-surgery syndrome: A systematic review and meta-analysis. *Curr Pain Headache Rep* 2020; 24:30.
13. Manchikanti L, Knezevic NN, Sanapati MR, Boswell MV, Kaye AD, Hirsch JA. Effectiveness of percutaneous adhesiolysis in managing chronic central lumbar spinal stenosis: A systematic review and meta-analysis. *Pain Physician* 2019; 22:E523-E550.
14. Manchikanti L, Soin A, Boswell MV, Kaye AD, Sanapati M, Hirsch JA. Effectiveness of percutaneous adhesiolysis in post lumbar surgery syndrome: A systematic analysis of findings of systematic reviews. *Pain Physician* 2019; 22:307-322.
15. Manchikanti L, Knezevic E, Knezevic NN, et al. The role of percutaneous neurolysis in lumbar disc herniation: Systematic review and meta-analysis. *Korean J Pain* 2021; 34:346-368.
16. Cho JH, Lee JH, Song KS, et al. Treatment outcomes for patients with failed back surgery. *Pain Physician* 2017; 20:E29-E43.
17. Manchikanti L, Knezevic NN, Navani A, et al. Epidural interventions in the management of chronic spinal pain: American Society of Interventional Pain Physicians (ASIPP) comprehensive evidence-based guidelines. *Pain Physician* 2021; 24:S27-S208.
18. Kaye AD, Manchikanti L, Abdi S, et al. Efficacy of epidural injections in managing chronic spinal pain: A best evidence synthesis. *Pain Physician* 2015; 18:E939-E1004.
19. Lee JH, Kim DH, Kim DH, et al. Comparison of clinical efficacy of epidural injection with or without steroid in lumbosacral disc herniation: A systematic review and meta-analysis. *Pain Physician* 2018; 21:449-468.
20. Manchikanti L, Benyamin RM, Falco FJ, Kaye AD, Hirsch JA. Do epidural injections provide short- and long-term relief for lumbar disc herniation? A systematic review. *Clin Orthop Relat Res* 2015; 473:1940-1956.
21. Manchikanti L, Knezevic NN, Boswell MV, Kaye AD, Hirsch JA. Epidural injections for lumbar radiculopathy and spinal stenosis: A comparative systematic review and meta-analysis. *Pain Physician* 2016; 19:E365-E410.
22. Knezevic N, et al. Lack of superiority of epidural injections with lidocaine with steroids compared to without steroids in spinal pain: A systematic review and meta-analysis. *Pain Physician* 2020; 23:S239-S270.
23. CGS Administrators, LLC. Local Coverage Determination (LCD). Lumbar Epidural Steroid Injections (ESI) (L34807). Revision Effective Date: 12/31/2020.
24. Shanthanna H, Busse J, Wang L, et al. Addition of corticosteroids to local anaesthetics for chronic non-cancer pain injections: A systematic review and meta-analysis of randomised controlled trials. *Br J Anaesth* 2020; 125:779-801.
25. Manchikanti L, Knezevic NN, Sanapati J, et al. Is epidural injection of sodium chloride solution a true placebo or an active control agent? A systematic review and meta-analysis. *Pain Physician* 2021; 24:41-59.
26. Manchikanti L, Knezevic NN, Parr A, Kaye AD, Sanapati M, Hirsch JA. Does epidural bupivacaine with or without steroids provide long-term relief? A systematic review and meta-analysis. *Curr Pain Headache Rep* 2020; 24:26.
27. Lee JH, Shin KS, Park SJ, et al. Comparison of clinical efficacy between transforaminal and interlaminar epidural injections in lumbosacral disc herniation: A systematic review and meta-analysis. *Pain Physician* 2018; 21:433-448.
28. Lee JH, Shin KH, Bahk SJ, et al. Comparison of clinical efficacy of transforaminal and caudal epidural steroid injection in lumbar and lumbosacral disc herniation: A systematic review and meta-analysis. *Spine J* 2018; 18:2343-2353.

29. Mesregah MK, Feng W, Huang WH, et al. Clinical effectiveness of interlaminar epidural injections of local anesthetic with or without steroids for managing chronic neck pain: A systematic review and meta-analysis. *Pain Physician* 2020; 23:335-348.
30. Zhao W, Wang Y, Wu J, et al. Long-term outcomes of epidurals with lidocaine with or without steroids for lumbar disc herniation and spinal stenosis: A meta-analysis. *Pain Physician* 2020; 23:365-374.
31. Bicket M, Gupta A, Brown CH, Cohen SP. Epidural injections for spinal pain: A systematic review and meta-analysis evaluating the “control” injections in randomized controlled trials. *Anesthesiology* 2013; 119:907-931.
32. Manchikanti L, Nampiaparampil DE, Manchikanti KN, et al. Comparison of the efficacy of saline, local anesthetics, and steroids in epidural and facet joint injections for the management of spinal pain: A systematic review of randomized controlled trials. *Surg Neurol Int* 2015; 6:S194-S235.
33. Manchikanti L, Kaye AD, Manchikanti KN, Boswell MV, Pampati V, Hirsch JA. Efficacy of epidural injections in the treatment of lumbar central spinal stenosis: A systematic review. *Anesth Pain Med* 2015; 5:e23139.
34. Helm II S, Harmon PC, Noe C, et al. Transforaminal epidural steroid injections. A systematic review and meta-analysis of efficacy and safety. *Pain Physician* 2021; 24:S209-S232.
35. Meng H, Fei Q, Wang B, et al. Epidural injections with or without steroids in managing chronic low back pain secondary to lumbar spinal stenosis: A meta-analysis of 13 randomized controlled trials. *Drug Des Devel Ther* 2015; 9:4657-4667.
36. Liu K, Liu P, Liu R, Wu X, Cai M. Steroid for epidural injection in spinal stenosis: A systematic review and meta-analysis. *Drug Des Devel Ther* 2015; 9:707-716.
37. Liu J, Zhou H, Lu L, et al. The effectiveness of transforaminal versus caudal routes for epidural steroid injections in managing lumbosacral radicular pain: A systematic review and meta-analysis. *Medicine (Baltimore)* 2016; 95:e3373.
38. Lee JH, Choi KH, Kang S, et al. Nonsurgical treatments for patients with radicular pain from lumbosacral disc herniation. *Spine J* 2019; 19:1478-1489.
39. Bhatia A, Flamer D, Shah PS, Cohen SP. Transforaminal epidural steroid injections for treating lumbosacral radicular pain from herniated intervertebral discs: A systematic review and meta-analysis. *Anesth Analg* 2016; 122:857-870.
40. Manchikanti L, Cash KA, Pampati V, Wargo BW, Malla Y. A randomized, double-blind, active control trial of fluoroscopic cervical interlaminar epidural injections in chronic pain of cervical disc herniation: Results of a 2-year follow-up. *Pain Physician* 2013; 16:465-478.
41. Manchikanti L, Cash KA, Pampati V, Malla Y. Two-year follow-up results of fluoroscopic cervical epidural injections in chronic axial or discogenic neck pain: A randomized, double-blind, controlled trial. *Int J Med Sci* 2014; 11:309-320.
42. Manchikanti L, Malla Y, Cash KA, Pampati V, Hirsch JA. Comparison of effectiveness for fluoroscopic cervical interlaminar epidural injections with or without steroid in cervical post-surgery syndrome. *Korean J Pain* 2018; 31:277-288.
43. Manchikanti L, Malla Y, Cash KA, McManus CD, Pampati V. Fluoroscopic epidural injections in cervical spinal stenosis: Preliminary results of a randomized, double-blind, active control trial. *Pain Physician* 2012; 15:E59-E70.
44. Manchikanti L, Cash KA, McManus CD, Pampati V, Benyamin RM. Thoracic interlaminar epidural injections in managing chronic thoracic pain: A randomized, double-blind, controlled trial with a 2-year follow-up. *Pain Physician* 2014; 17:E327-E338.
45. Manchikanti L, Cash KA, Pampati V, Falco FJE. Transforaminal epidural injections in chronic lumbar disc herniation: A randomized, double-blind, active-control trial. *Pain Physician* 2014; 17:E489-E501.
46. Manchikanti L, Singh V, Cash KA, Pampati V, Falco FJE. A randomized, double-blind, active-control trial of the effectiveness of lumbar interlaminar epidural injections in disc herniation. *Pain Physician* 2014; 17:E61-E74.

47. Manchikanti L, Cash KA, McManus CD, Pampati V, Benyamin RM. A randomized, double-blind, active-controlled trial of fluoroscopic lumbar interlaminar epidural injections in chronic axial or discogenic low back pain: Results of a 2-year follow-up. *Pain Physician* 2013; 16:E491-E504.
48. Manchikanti L, Cash KA, McManus CD, Damron KS, Pampati V, Falco FJE. A randomized, double-blind controlled trial of lumbar interlaminar epidural injections in central spinal stenosis: 2-year follow-up. *Pain Physician* 2015; 18:79-92.
49. Manchikanti L, Singh V, Cash KA, Pampati V, Damron KS, Boswell MV. Effect of fluoroscopically guided caudal epidural steroid or local anesthetic injections in the treatment of lumbar disc herniation and radiculitis: A randomized, controlled, double blind trial with a two-year follow-up. *Pain Physician* 2012; 15:273-286.
50. Manchikanti L, Cash KA, McManus CD, Pampati V. Fluoroscopic caudal epidural injections in managing chronic axial low back pain without disc herniation, radiculitis or facet joint pain. *J Pain Res* 2012; 5:381-390.
51. Manchikanti L, Cash KA, McManus CD, Pampati V, Fellows B. Results of 2-year follow-up of a randomized, double-blind, controlled trial of fluoroscopic caudal epidural injections in central spinal stenosis. *Pain Physician* 2012; 15:371-384.
52. Manchikanti L, Singh V, Cash KA, Pampati V, Datta S. Fluoroscopic caudal epidural injections in managing post lumbar surgery syndrome: Two-year results of a randomized, double-blind, active-control trial. *Int J Med Sci* 2012; 9:582-591.
53. Friedly JL, Comstock BA, Turner JA, et al. A randomized trial of epidural glucocorticoid injections for spinal stenosis. *N Engl J Med* 2014; 371:11-21.
54. The National Uniform Claims Committee. Specialty Designation for Interventional Pain Management-09. <http://www.cms.hhs.gov/transmittals/Downloads/r1779b3.pdf>.
55. Medicare Payment Advisory Commission. Report to the Congress: Paying for interventional pain services in ambulatory settings. Washington, DC: MedPAC. December 2001. <http://medpac.gov/docs/default-source/reports/december-2001-report-to-the-congress-paying-for-interventional-pain-services-in-ambulatory-settings.pdf?sfvrsn=0>.
56. Cho PG, Ji GY, Yoon YS, Shin DA. Clinical effectiveness of percutaneous epidural neuroplasty according to the type of surgical level lumbar disc herniation: A 12 month follow up study. *J Korean Neurosurg Soc* 2019; 62: 681-690.
57. Moon SH, Lee JI, Cho HS, Shin JW, Koh WU. Factors for predicting favorable outcome of percutaneous epidural adhesiolysis for lumbar disc herniation. *Pain Res Manag* 2017; 2017: 1494538.
58. Park SH, Ji GY, Cho PG, Shin DA, Yoon YS, Kim KN, et al. Clinical significance of epidurography contrast patterns after adhesiolysis during lumbar percutaneous epidural neuroplasty. *Pain Res Manag* 2018; 2018: 6268045.
59. Choi EJ, Yoo YJ, Lee PB, Kim YC, Lee SC, Moon JY. A retrospective study to evaluate the effect of concentration of hypertonic saline on efficacy and safety of epidural adhesiolysis. *Anesth Analg* 2017; 124: 2021-2029.
60. Ji GY, Oh CH, Moon B, Choi SH, Shin DA, Yoon YS, et al. Efficacy of percutaneous epidural neuroplasty does not correlate with dural sac cross-sectional area in single level disc disease. *Yonsei Med J* 2015; 56: 691-697.
61. Murakibhavi VG, Khemka AG. Caudal epidural steroid injection: A randomized controlled trial. *Evid Based Spine Care J* 2011; 2:19-26.
62. Ghai B, Kumar K, Bansal D, Dhatt SS, Kanukula R, Batra YK. Effectiveness of parasagittal interlaminar epidural local anesthetic with or without steroid in chronic lumbosacral pain: A randomized, double-blind clinical trial. *Pain Physician* 2015; 18:237-248.
63. Ökmen K, Ökmen BM. The efficacy of interlaminar epidural steroid administration in multilevel intervertebral disc disease with chronic low back pain: A randomized, blinded, prospective study. *Spine J* 2017; 17:168-174.

64. Karppinen J, Malmivaara A, Kurunlahti M, et al. Periradicular infiltration for sciatica: A randomized controlled trial. *Spine (Phila Pa 1976)* 2001; 26:1059-1067.
65. Riew KD, Yin Y, Gilula L, et al. The effect of nerve-root injections on the need for operative treatment of lumbar radicular pain: A prospective, randomized, controlled, double-blind study. *J Bone Joint Surg Am* 2000; 82:1589-1593.
66. Riew D, Park JB, Cho YS, et al. Nerve root blocks in the treatment of lumbar radicular pain. A minimum five-year follow-up. *J Bone Joint Surg Am* 2006; 88:1722-1725.
67. Tafazal S, Ng L, Chaudhary N, Sell P. Corticosteroids in peri-radicular infiltration for radicular pain: A randomised double blind controlled trial: one year results and subgroup analysis. *Eur Spine J* 2009; 18:1220-1225.
68. Ackerman WE 3rd, Ahmad M. The efficacy of lumbar epidural steroid injections in patients with lumbar disc herniations. *Anesth Analg* 2007; 104:1217-1222.
69. Dashfield A, Taylor M, Cleaver J, Farrow D. Comparison of caudal steroid epidural with targeted steroid placement during spinal endoscopy for chronic sciatica: A prospective, randomized, double-blind trial. *Br J Anaesth* 2005; 94:514-519.
70. Kamble PC, Sharma A, Singh V, Natraj B, Devani D, Khapane V. Outcome of single level disc prolapse treated with transforaminal steroid versus epidural steroid versus caudal steroids. *Eur Spine J* 2016; 25:217-221.
71. Pandey RA. Efficacy of epidural steroid injection in management of lumbar prolapsed intervertebral disc: A comparison of caudal, transforaminal and interlaminar routes. *J Clin Diagn Res* 2016; 10:RC05-11.
72. Singh S, Kumar S, Chahal G, Verma R. Selective nerve root blocks vs. caudal epidural injection for single level prolapsed lumbar intervertebral disc - A prospective randomized study. *J Clin Orthop Trauma* 2017; 8:142-147.
73. Rados I, Sakic K, Fingler M, Kapural L. Efficacy of interlaminar vs transforaminal epidural steroid injection for the treatment of chronic unilateral radicular pain: Prospective, randomized study. *Pain Med* 2011; 12:1316-1321.
74. Ghai B, Bansal D, Kay JP, Vadaje KS, Wig J. Transforaminal versus parasagittal interlaminar epidural steroid injection in low back pain with radicular pain: A randomized, double-blind, active-control trial. *Pain Physician* 2014; 17:277-290.
75. Candido KD, Rana MV, Sauer R, et al. Concordant pressure paresthesia during interlaminar lumbar epidural steroid injections correlates with pain relief in patients with unilateral radicular pain. *Pain Physician* 2013; 16:497-511.
76. Amr YM. Effect of addition of epidural ketamine to steroid in lumbar radiculitis: One-year follow-up. *Pain Physician* 2011; 14:475-481.
77. Vad VB, Bhat AL, Lutz GE, Cammisa F. Transforaminal epidural steroid injections in lumbosacral radiculopathy: A prospective randomized study. *Spine (Phila Pa 1976)* 2002; 27:11-16.
78. Jeong HS, Lee JW, Kim SH, Myung JS, Kim JH, Kang HS. Effectiveness of transforaminal epidural steroid injection by using a preganglionic approach: A prospective randomized controlled study. *Radiology* 2007; 245:584-590.
79. Kennedy D, Plastaras C, Casey E, et al. Comparative effectiveness of lumbar transforaminal epidural steroid injections with particulate versus nonparticulate corticosteroids for lumbar radicular pain due to intervertebral disc herniation: A prospective, randomized, double-blind trial. *Pain Med* 2014; 15:548-555.
80. Manchikanti L, Pampati V, Parr III A, et al. Cervical interlaminar epidural injections in the treatment of cervical disc herniation, post surgery syndrome, or discogenic pain: Cost utility analysis from randomized trials. *Pain Physician* 2019; 22:421-431.
81. Manchikanti L, Falco FJE, Pampati V, Cash KA, Benyamin RM, Hirsch JA. Cost utility analysis of caudal epidural injections in the treatment of lumbar disc herniation, axial or discogenic low back pain, central spinal stenosis, and post lumbar surgery syndrome. *Pain Physician* 2013; 16:E129-E143.

82. Manchikanti L, Pampati V, Sanapati SP, Sanapati MR, Kaye AD, Hirsch JA. Evaluation of cost-utility of thoracic interlaminar epidural injections. *Curr Pain Headache Rep* 2020; 24:5.
83. Manchikanti L, Pampati V, Benyamin RM, Hirsch JA. Cost utility analysis of lumbar interlaminar epidural injections in the treatment of lumbar disc herniation, central spinal stenosis, and axial or discogenic low back pain. *Pain Physician* 2017; 20:219-228.
84. Manchikanti L, Schultz DM, Atluri S, Glaser SE, Falco FJE. Lumbar epidural injections. In: Manchikanti L, Kaye AD, Falco FJE, Hirsch JA (eds). *Essentials of Interventional Techniques in Managing Chronic Spinal Pain*. Springer, New York, NY, 2018, pp 141-186.
85. Murthy NS, Maus TP, Behrns CL. Intraforaminal location of the great anterior radiculomedullary artery (artery of Adamkiewicz): A retrospective review. *Pain Med* 2010; 11:1756-1764.
86. van Roy P, Barbaix E, Clarijs JP, et al. Anatomical background of low back pain: variability and degeneration of the lumbar spinal canal and intervertebral disc. *Schmerz* 2001; 15:418-424