

Leucocyte-Rich Platelet-Rich Plasma Treatment of Gluteus Medius and Minimus Tendinopathy

A Double-Blind Randomized Controlled Trial With 2-Year Follow-up

Jane Fitzpatrick,^{*†‡§} PhD, MBBS, FACSEP, Max K. Bulsara,^{||} PhD, John O'Donnell,[¶] FRACS, MBBS, and Ming Hao Zheng,^{#**} PhD, DM, FRCPath, FRCPA
Investigation performed at the University of Western Australia, Crawley, Australia

Background: A previously published trial showed that patients with chronic gluteal tendinopathy achieved greater clinical improvement at 12 weeks when treated with a single platelet-rich plasma (PRP) injection than those treated with a single corticosteroid injection (CSI).

Purpose: This follow-up study was conducted to determine whether there would be a sustained long-term difference in the modified Harris Hip Score (mHHS) at 2 years for a leucocyte-rich PRP (LR-PRP) injection in the treatment of chronic gluteal tendinopathy.

Study Design: Randomized controlled trial; Level of evidence, 1.

Methods: This trial included 80 patients randomized 1:1 to receive LR-PRP or CSI intratendinously under ultrasound guidance. Patients had a mean age of 60 years, a 9:1 ratio of women to men, a mean body mass index of 27, and a mean length of symptoms >15 months. No patients had full-thickness tears of the gluteal tendons. An open-labeled extension allowed patients to receive crossover treatment after 3 months. The main outcome measure was the mHHS.

Results: The mean mHHS improved significantly at 12 weeks in the PRP group (74.05; SD, 13.92) as compared with the CSI group (67.13; SD, 16.04) ($P = .048$). At 24 weeks, the LR-PRP group (77.60; SD, 11.88) improved further than the CSI group (65.72; SD, 15.28; $P = .0003$). Twenty-seven patients were deemed to have failed the CSI treatment at 16 to 24 weeks, with an exit score of 59.22 (SD, 11.54), and then had treatment with LR-PRP. The crossover group improved with the LR-PRP: from 59.22 (SD, 11.22) at baseline to 75.55 (SD, 16.05) at 12 weeks, 77.69 (SD, 15.30) at 24 weeks, and 77.53 (SD, 14.54) at 104 weeks. The LR-PRP group retained 38 of 39 patients to 52 weeks and continued to improve. Their baseline scores of 53.77 (SD, 12.08) improved to 82.59 (SD, 9.71) at 104 weeks ($P < .0001$).

Conclusion: Among patients with chronic gluteal tendinopathy and a length of symptoms >15 months, a single intratendinous LR-PRP injection performed under ultrasound guidance results in greater improvement in pain and function than a single CSI. The improvement after LR-PRP injection is sustained at 2 years, whereas the improvement from a CSI is maximal at 6 weeks and not maintained beyond 24 weeks.

Registration: ACTRN12613000677707 (Australian New Zealand Clinical Trials identifier).

Keywords: tendinitis; greater trochanteric pain syndrome; trochanteric bursitis; PRP

Gluteal tendinopathy of the gluteus medius or minimus tendons is acknowledged as one of the primary causes of lateral hip pain or greater trochanteric pain syndrome. It is >4 times more prevalent among middle-aged women than men

and is the most prevalent of all lower limb tendinopathies.¹⁰ Walsh et al³⁵ reported that 10% to 40% of patients with gluteal tendinopathy fail nonoperative treatment. Significant levels of dysfunction were noted among people with gluteal tendinopathy, which was equated to the level of disability of severe osteoarthritis of the hip.¹² Thus, long-term effective strategies for the treatment of gluteal tendinopathy are important for the well-being of this group.

The cause of tendinopathy of the gluteal tendons is unknown. The clinical history of gluteal tendinitis suggests

a degenerative progression of disease.^{4,7,23} In early cases, tendinopathy of one or both tendons is sometimes present with secondary trochanteric bursitis.^{6,19} Moderate cases show partial-thickness tears longitudinally or at the insertion of the tendons.^{6,18} More advanced cases demonstrate full-thickness tears with progression to tendon retraction and fatty atrophic changes of the muscle belly, as seen on magnetic resonance imaging.¹⁹

Bhabra et al³ described the cellular mechanism for this progression of degenerative change in tendinopathy, where a cycle of microtrauma and improper healing leads to tendinopathy and eventual structural failure in tendons. Four grades of tendinopathy are described. In grade 1, the collagen fiber pattern becomes increasingly wavy. Although cellular and vascular changes are minimal, there is an increase in the proportion of type 3 collagen. In grade 2, there is tendinosis and angiofibroblastic hyperplasia, with further disorganization and fragmentation of the collagen fibers, cellular hyperplasia, rounding of tenocytes, and neovascular hyperplasia. In grade 3, programmed cell death leads to the depletion of functional tendon cells and breakdown of collagen and extracellular matrix. Finally, grade 4 presents with gross structural disruption and mechanical failure.

Each stage of tendinopathy responds differently to different treatment modalities.⁴ Acute cases of tendinopathy were shown to benefit from physical therapy interventions, analgesics, and nonsteroidal anti-inflammatory drugs.^{24,30,36} The use of corticosteroid injections (CSIs) may provide short-term benefits from 12 to 26 weeks, but the recurrence rate is high.^{28,30,31,36} If the tendon has a full-thickness tear, nonoperative measures are generally ineffective, and these patients are often treated surgically.^{1,8,24,32,33}

Given the paucity of treatments for higher-grade tendinopathy, there is interest in whether biological treatments might provide a better long-term outcome for patients. A recent meta-analysis on the use of platelet-rich plasma (PRP) in tendinopathy found that a single leucocyte-rich PRP (LR-PRP) injection showed positive outcomes in the management of tendinopathy.¹³ Further laboratory study showed that different PRP kits and preparation produce varying levels of platelets and white cells, even when PRP is made with the buffy coat layer.¹⁴

Fitzpatrick et al¹⁵ performed a double-blind randomized controlled trial assessing the effectiveness of a single LR-PRP injection as compared with a single CSI in the management of gluteal tendinopathy. A total of 228 patients were screened to enroll 80 participants with a mean age

of 60 years, a 9:1 ratio of females, a mean body mass index of 27, and a mean length of symptoms of 15 months. Patients were randomized to receive LR-PRP or CSI intratendinously under ultrasound guidance. The mean modified Harris Hip Score (mHHS) improved significantly at 12 weeks in the PRP group (74.05; SD, 13.92) as compared with the CSI group (67.13; SD, 16.04; $P = .048$). The number of patients who achieved the minimal clinically important difference (ie, a change in score >8 points from baseline to 12 weeks) was 21 of 37 (56.7%) in the CSI group and 32 of 39 (82%) in the PRP group ($P = .016$). While the 3-month follow-up showed that the effectiveness of CSI was maximal at 2 to 6 weeks and that the effect of PRP was emerging at 12 weeks, the clinical results need to be sustained beyond 12 months for this to be an effective long-term treatment. This study presents the follow-up of these patients out to 2 years.

Our hypothesis was that there would be a sustained difference in the mHHS at 2 years for the LR-PRP injection in the treatment of chronic gluteal tendinopathy.

METHODS

Trial Design

This double-blind randomized controlled trial with open-labeled extension to 2 years included 80 patients randomized 1:1 to receive either LR-PRP or CSI intratendinously under ultrasound guidance between May 2013 and May 2015. Two-year follow-up was completed in June 2017. This trial was registered at the Australian New Zealand Clinical Trials Registry (ACTRN12613000677707) and undertaken with ethics approval from the Epworth Healthcare Human Research Ethics Committee (57412). The full trial design is outlined in the 3-month follow-up report,¹⁵ and it followed CONSORT (Consolidated Standards of Reporting Trials) guidelines. No changes were made to the trial design after commencement.

Patient Selection. Patients had a mean age of 60 years (range, 23-78 years), a 9:1 ratio of women to men, a mean body mass index of 27 (SD, 4.48), and a mean length of symptoms of 15 months (SD, 12.35). Eligible patients were 18 to 80 years old and had a history of gluteal tendinopathy >4 months—with symptoms including lateral hip pain, pain with activity (eg, walking and stair climbing), and pain lying on the affected side at night

*Address correspondence to Jane Fitzpatrick, PhD, MBBS, FACSEP, Faculty of Medicine, Dentistry and Health Science, University of Melbourne, Alan Gilbert Building, Level 7, 161 Barry Street, Parkville, VIC 3010, Australia (email: jane.fitzpatrick@unimelb.edu.au).

[†]Faculty of Medicine, Dentistry and Health Science, University of Melbourne, Parkville, Australia.

[‡]Joint Health Institute, Melbourne, Australia.

[§]Epworth Hospital, Richmond, Australia.

^{||}Institute for Health Research, University of Notre Dame, Fremantle, Australia.

[#]Hip Arthroscopy Australia, Richmond, Australia.

[#]Research Centre for Translational Orthopaedic Research, Sir Charles Gairdner Hospital, Nedlands, Australia.

^{**}School of Surgery, University of Western Australia, Crawley, Australia.

One or more of the authors has declared the following potential conflict of interest or source of funding: Zimmer Biomet USA provided the GPS III PRP separation kits used in this trial. J.F. has been on the Medical Advisory Board for Bioventus Global. J.O. is a consultant for Medacta and Smith & Nephew. M.H.Z. is a consultant for and holds shares in Orthocell. AOSSM checks author disclosures against the Open Payments Database (OPD). AOSSM has not conducted an independent investigation on the OPD and disclaims any liability or responsibility relating thereto.

TABLE 1
Patient Data^a

Characteristic	CSI (n = 40)	LR-PRP (n = 40)	P Value ^b
Age, y, mean ± SD	59.7 (23-78)	60.3 (23-76)	.93
Sex			.13
Male	2 (5)	6 (15)	
Female	38 (95)	34 (85)	
Body mass index, kg/m ² , mean ± SD (range)	26.96 ± 4.33 (18.8-39.5)	28.42 ± 4.58 (20-43.9)	.15
Previous CSI			
0	21 (52.5)	13 (32.5)	
1	14 (35)	19 (47.5)	
2	3 (7.5)	6 (15)	
≥3	2 (5)	2 (5)	
Group, mean ± SD	0.65 ± 0.83	0.98 ± 0.97	.11
Length of symptoms, mo			
<12	19 (47.5)	23 (57.5)	
12	11 (27.5)	8 (20)	
24	6 (15)	6 (15)	
36	2 (5)	2 (5)	
48	1 (2.5)	0 (0)	
60	1 (2.5)	1 (2.5)	
Group, mean ± SD	15.25 ± 15.52	14.78 ± 12.33	.88
Initial mHHS, mean ± SD (range)	54.15 ± 10.88 (32-71)	53.77 ± 12.08 (23-77)	.88

^aData reported as n (%), unless otherwise noted. CSI, corticosteroid injection; LR-PRP, leucocyte-rich platelet-rich plasma; mHHS, modified Harris Hip Score.

^bPaired *t* test.

and with clinical signs on examination including tenderness over the greater trochanter. Radiological confirmation of the diagnosis of grade 2-3 tendinopathy (no tear) was made with ultrasound and magnetic resonance imaging. Tendon pathology was graded as follows: grade 1, bursitis (with minimal change in the tendon); grade 2, tendinopathy of one or both tendons; grade 3, partial-thickness tear; and grade 4, full-thickness tear of either tendon. All patients had at least minor changes consistent with tendinopathy radiologically and a clinical diagnosis of gluteal tendinopathy and were excluded if they had full-thickness tears.

Exclusion criteria were full-thickness tears (grade 4) demonstrated radiologically, previous hip or tendon surgery, a history of breast cancer, warfarin use (ie, blood thinners) at the time of the procedure, back surgery within the past 12 months, a history of recent sciatica, a cortisone injection within the previous 6 weeks, and the absence of physical therapy. Table 1 presents full patient characteristics.

Intervention. The PRP was prepared with the GPS III Kit (Biomet Biologics), which was demonstrated to produce LR-PRP.¹⁴ Table 2 identifies the characteristics of the PRP preparation according to the recommendations of Murray et al²⁷ and based on our previously published study of the GPS III preparation of PRP.

Both groups had the same 12-week unsupervised rehabilitation program with directed activity modification posttreatment without engagement of clinical physiotherapists. In the first 4 weeks, patients were instructed to avoid all aggravating activities, including walking for exercise, stairs, squats, lunges, and abduction exercises. At 6 weeks, they were instructed to begin a progressive walking program, which

included the use of stairs, a return to the gym, and other sports. There were no limitations on the patient's activity after 12 weeks.¹⁵

Outcomes. The primary outcome measure was the mHHS—a pain and functional assessment. The mHHS was completed by the patients at baseline and 2, 6, and 12 weeks and then at 6, 12, and 24 months.

The patient acceptable symptomatic state (PASS) was used to determine when clinical recovery had been achieved²¹ and was determined by a score ≥74, as defined by Chahal et al.⁵

Blinding. Patients and investigators were blinded for a minimum of 3 months. After this, patients were unblinded if they determined that they had not made a recovery and requested further treatment. Patients remained blinded until June 2017 if they did not have any further intervention.

Crossover. Patients were offered further treatment in the form of a cortisone injection, an LR-PRP injection, or surgical intervention if they failed treatment beyond 3 months. This was unblinded.

Statistical Assessment

Statistical analysis was conducted on an as-treated basis with Stata (v 14; StataCorp). Treatment comparisons were based on the mHHS at 3, 6, 12, and 24 months by group analysis with a significance of *P* < .05. Standard *t* tests with equal variance were done at 24 weeks. No change was made to the sample size analysis from the

TABLE 2
PRP Characteristics^a

PRP processing	
Details of the kit	GPS III Kit, Biomet Biologics (Zimmer Biomet USA)
PRP spin protocol	Centrifugal force, 1100g; time, 15 min
Volume of blood taken/additives	52 mL, blood; ACD-A, 8 mL
PRP storage temperature and light exposure	Used immediately, no additional light exposure
PRP characteristics	
Format	Liquid
PRP platelet concentration	$964 \times 10^9/L$ (SD, $551 \times 10^9/L$) ¹⁴
PRP leucocyte concentration	$35.8 \times 10^9/L$ (SD, $10.8 \times 10^9/L$) ¹⁴
Differential leucocyte count	
Neutrophils	$15.4 \times 10^9/L$ (SD, $5.05 \times 10^9/L$) ¹⁴
Lymphocytes	$15.9 \times 10^9/L$ (SD, $7.73 \times 10^9/L$) ¹⁴
Monocytes	$3.8 \times 10^9/L$ (SD, $1.1 \times 10^9/L$) ¹⁴
PRP RBC concentration	$1.03 \times 10^9/L$ (SD, $0.289 \times 10^9/L$) ¹⁴
Activation	
Type, time	No activation
Delivery	
Time from processing to delivery	Used immediately after preparation
Time from activation to delivery	Not applicable
Point of delivery	Outpatient private rooms, single injection
Site of delivery	Gluteal tendon, ultrasound guided, intratendinous
Volume delivered	6-7 mL
Details of carrier	Nil
Concomitant use of stem cells, etc	Nil

^aACD-A, anticoagulant citrate dextrose solution–formula A; PRP, platelet-rich plasma; RBC, red blood cell.

previous study. A power analysis determined the total sample size at 72 (36 in each group) based on a minimal clinically important difference of 8 points. To account for a 10% dropout rate at 12 weeks, 80 patients were recruited to the study.

RESULTS

Patient Study and Follow-up

Figure 1 shows the flow of participants in each group. Eighty patients were randomly assigned to the LR-PRP treatment group ($n = 40$) and the CSI group ($n = 40$). The results to 12 weeks were previously published, where data for 37 patients in the CSI group and 39 in the LR-PRP group were analyzed.

After 12 weeks, patients who requested further treatment (owing to treatment failure) were offered crossover treatment in the form of a cortisone injection, an LR-PRP injection, or surgical intervention. This was unblinded. Of the 37 patients in the CSI group, 10 remained blinded as treated at 104 weeks; 27 crossed to the CSI + LR-PRP group (within this subgroup, 3 failed the LR-PRP and were referred for surgery). All 37 patients were available for analysis within their crossover groups at 104 weeks. Of the 39 patients in the LR-PRP group at 12 weeks, 2 crossed over to surgery, and 2 were lost to follow-up, leaving 37 patients available for analysis at 104 weeks.

The mean mHHS improved significantly at 12 weeks in the PRP group (74.05; SD, 13.92) as compared with the CSI group (67.13; SD, 16.04; $P = .048$). At 24 weeks, the mean

mHHS in the LR-PRP group (77.60; SD, 11.88) had improved further than that of the CSI group (65.72; SD, 15.28; $P = .0003$) (Figure 2, Table 3). The LR-PRP group retained 38 patients to 52 weeks and continued to improve; from a baseline score of 53.77 (SD, 12.08), the scores improved to 78.18 (SD, 14.53; $P = .0002$) at 52 weeks and 82.59 (SD, 9.71; $P < .0001$) at 104 weeks (Figure 3).

Since the demographic data indicate that this condition is more prevalent in women (9:1), a further subgroup analysis was performed (Table 4). In this subgroup, the men did better than the women overall.

Between 16 and 24 weeks, patients from either group who requested further treatment continued to be followed but formed new groups. The largest number was from group 1 (CSI) that was then followed up as group 3 (CSI + LR-PRP). The patients' exit scores are recorded with the remaining 24-month scores and are presented in Table 3 as the time 0 score for group 3. Twenty-seven patients were deemed to have failed the CSI treatment at 16 to 52 weeks with a mean exit score of 59.22 (SD, 11.54), having almost returned to their mean baseline score of 54.15 (SD, 10.88). The remaining 15 patients retained a mean score of 70.53 (SD, 23.80) at 52 weeks, but by 104 weeks, only 10 remained, with a mean score of 71.27 (SD, 25.78).

The crossover group (CSI + LR-PRP) had baseline scores equivalent to the other 2 groups. It had returned to its baseline before having the crossover treatment, and it improved progressively from baseline (59.22; SD, 11.22) to 12 weeks (75.55; SD, 16.05), 24 weeks (77.69; SD, 15.30), and 104 weeks (77.53; SD, 14.54). Figure 4 presents a comparison with group 2 (LR-PRP), where the scores follow the same pattern.

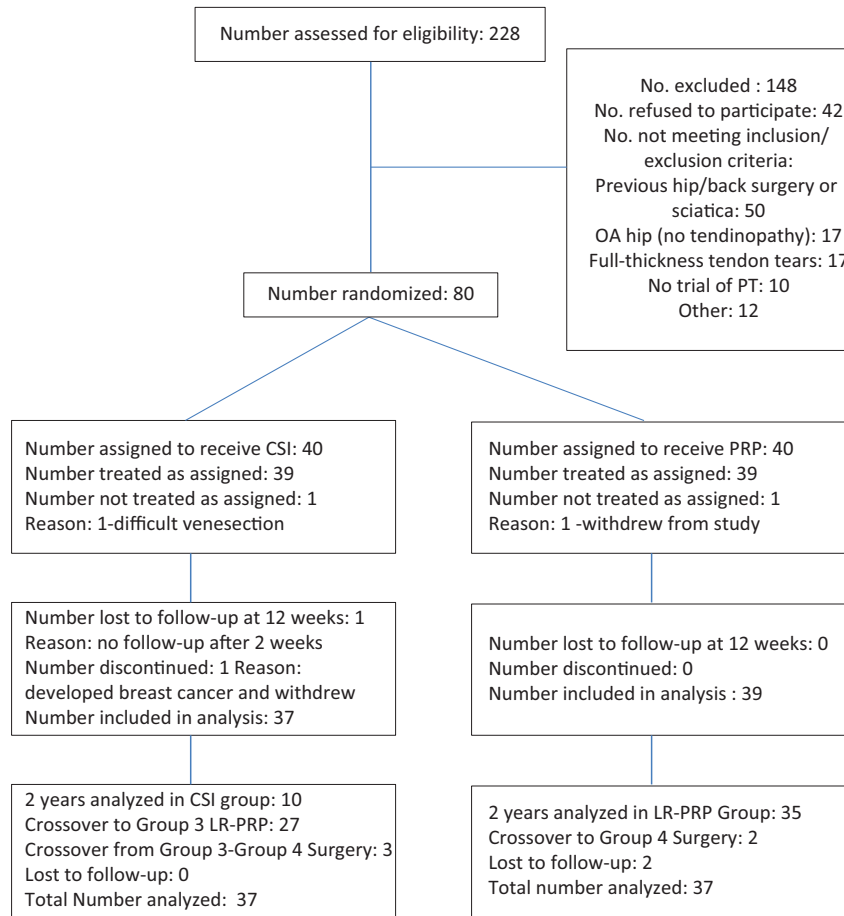


Figure 1. CONSORT (Consolidated Standards of Reporting Trials) flow diagram: LR-PRP in gluteal tendinopathy to 104 weeks. CSI, corticosteroid injection; LR-PRP, leucocyte-rich platelet-rich plasma; OA, osteoarthritis; PRP, platelet-rich plasma.

TABLE 3
mHHS at All Time Points for Each Group^a

Time Point, wk	CSI	LR-PRP	CSI+LR-PRP ^b	Surgery
0	40; 54.15 ± 10.88	40; 53.77 ± 12.08		
2	39; 66.95 ± 15.14	39; 65.23 ± 11.59		
6	37; 69.51 ± 14.78	39; 68.79 ± 13.32		
12	37; 67.13 ± 16.04	39; 74.05 ± 13.92		
24 (T2 = 0, group 3)	37; 65.72 ^c ± 15.28	38; 77.60 ± 11.88	27; 59.22 ^c ± 11.54	
26 (T2 + 2 wk)			27; 67.48 ± 13.97	
30 (T2 + 6 wk)			27; 70.37 ± 15.21	
36 (T2 + 12 wk)			27; 75.55 ± 16.05	
48 (T2 + 26 wk)			26; 77.69 ± 15.30	
52	15; 70.53 ± 23.80	38; 78.18 ± 14.53		3; 57.66 ± 10.96
76 (T2 + 52 wk)			21; 79.04 ± 14.28	
104	10; 71.27 ± 25.78	35; 82.59 ± 9.71		5; 67.80 ± 13.33
128 (T2 + 104 wk)			13; 77.53 ± 14.54	

^aData reported as n; mHHS, mean ± SD. CSI, corticosteroid injection; LR-PRP, leucocyte-rich platelet-rich plasma; mHHS, modified Harris Hip Score.

^bScores for this group are recorded from a new baseline, where time point 0 (ie, T2) is the new starting point after crossover from group 1 (CSI) after 24 weeks.

^cScores at approximately 24 weeks. The 24-week score is recorded once for each patient but represents either the last score taken before crossover or the continuing score if no crossover occurred.

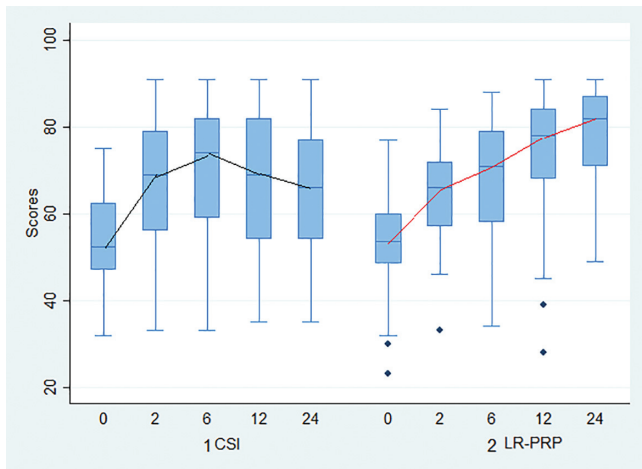


Figure 2. Modified Harris Hip Scores in the CSI and LR-PRP groups at 0, 2, 6, 12, and 24 weeks. CSI, corticosteroid injection; LR-PRP, leucocyte-rich platelet-rich plasma. Values are presented as median, interquartile range, 95% CI, and outliers.

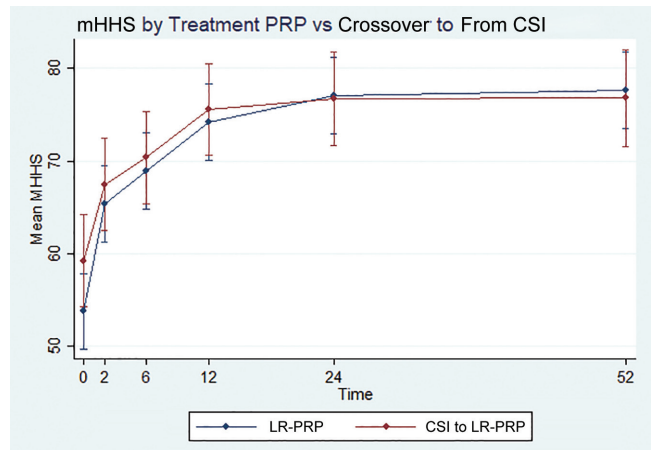


Figure 4. Modified Harris Hip Scores (mHHSs) in the LR-PRP and CSI + LR-PRP groups at 0 to 52 weeks. CSI, corticosteroid injection; LR-PRP, leucocyte-rich platelet-rich plasma. Values are presented as mean \pm SD.

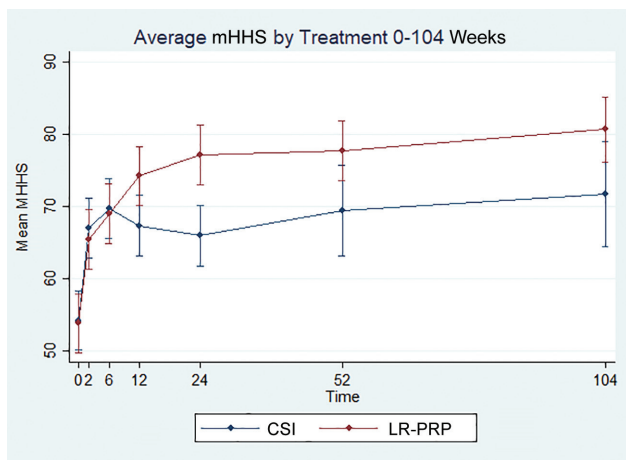


Figure 3. Modified Harris Hip Scores (mHHSs) in the CSI and LR-PRP groups at 0 to 104 weeks. CSI, corticosteroid injection; LR-PRP, leucocyte-rich platelet-rich plasma. Values are presented as mean \pm SD.

Overall, 5 patients failed their treatment and progressed to surgery: 2 from group 2 (LR-PRP) and 3 from group 1 (CSI). All 3 patients from the CSI group had LR-PRP and then surgery. PASS scores ≥ 74 were used to determine the number of patients who had fully recovered after their treatment, and the outcomes are presented in Table 5.

Only 4 patients were lost to follow-up at 2 years. Overall, at 24 weeks, only 10 of 37 (27%) patients in the CSI group had achieved the PASS score, as opposed to 25 of 38 (65.8%) in the LR-PRP group. By 2 years, only 8 patients remained in the CSI group with a PASS score ≥ 74 (8 of 37 [21%] of the initial group). By contrast, in the LR-PRP group, 31 of 35 (88.6%; or 31 of 39 [79.5%] of the initial group) had reached a PASS score ≥ 74 .

TABLE 4
mHHS Subgroup Analysis at 104 Weeks by Sex^a

Group	CSI	LR-PRP
Female	63.8 \pm 13.5	80.48 \pm 10.34 ^b
Male	88 \pm 0	87.75 \pm 3.77
Combined	71.27 \pm 25.78	82.59 \pm 9.71

^aData reported as mHHS, mean \pm SD. CSI, corticosteroid injection; LR-PRP, leucocyte-rich platelet-rich plasma; mHHS, modified Harris Hip Score.

^b*P* = .014.

DISCUSSION

This study compared long-term pain and function outcomes as measured by the mHHS among patients with chronic or natural history resistant tendinopathy receiving a CSI or an LR-PRP injection for gluteal tendinopathy. The blinded results of the study were reported at 12-week follow-up and showed a statistically significant improvement in the LR-PRP group as compared with the CSI group. The results at 24 weeks further demonstrated that the mean effect of the CSI (65.72; SD, 15.28) had declined, as shown by previous authors,^{22,24,28,30} and that the LR-PRP group had a sustained improvement (77.60; SD, 1.88; *P* = .0003). This effect was also sustained at 12 months (78.18; SD, 14.53) and 2 years (82.59; SD, 9.71).

The use of PRP in the treatment of tendinopathy has been controversial.²⁶ Some tendons may be different in their response (eg, Achilles tendon).⁹ Part of the reason for this controversy lies in the fact that PRP has a slow onset of action and that it takes 3 to 6 months to see the effectiveness.^{2,16,17,25,34} It has been difficult to get statistical significance over times < 3 months or with small numbers of participants.^{11,20,29} This study showed a slow onset

TABLE 5
PASS Scores ≥ 74 at 12, 24, 52, and 104 Weeks^a

Time Point, wk	CSI	LR-PRP	CSI + LR-PRP
12	17 of 37 (45.9)	25 of 39 (64.1)	18 of 27 (66.6)
24	10 of 37 (27)	25 of 38 (65.8)	18 of 26 (69.2)
52	9 of 15 (60)	29 of 38 (76.34)	15 of 21 (71.4)
104	8 of 10 (80)	31 of 35 (88.6)	9 ^b of 13 (69.2)

^aData reported as n (%). CSI, corticosteroid, injection; LR-PRP, leucocyte-rich platelet-rich plasma; PASS, patient acceptable symptomatic state.

^bNote that this group commenced the crossover at 16 to 52 weeks; as such, not all patients reached the 104 weeks at the assessment time.

of action in the first 6 weeks. The mean mHHS changed 15.02 points by 6 weeks: from 53.77 (SD, 12.08) to 68.79 (SD, 13.32). Twelve weeks marked the first time point where patients reached the PASS score showing recovery, and then there was continued improvement out to 1 year, when the change was much greater at 24.41 points: from 53.77 (SD, 12.08) to 78.18 (SD, 14.53). Interestingly, and perhaps unexpectedly, there was further improvement from 1 to 2 years, where the mean mHHS reached 82.59 (SD, 9.71). This may represent the ongoing cellular and structural adaptations occurring in the tendon. This will be explored in a subsequent study examining the radiological findings beyond 24 months.

The second reason for the controversy is that it is difficult to get patients in a control group to avoid dropout when they have no clinical effect from the control treatment or a short-term benefit only. This was reported by several groups.^{20,25,29} The use of placebo or inactive controls makes this more difficult owing to the long time frame required to reach the full effect of the PRP. This study aimed to avoid this by ending the blinding at 3 months and allowing a crossover treatment so that patients were not lost to follow-up. Only 1 patient from the control group (CSI) was lost to follow-up at 12 months and 2 from the LR-PRP group.

The type of PRP used has also been controversial. This study focused on the use of LR-PRP and demonstrated a very positive outcome in the long term. Fitzpatrick et al¹³ demonstrated that LR-PRP and, in particular, the GPS III kit showed good results in the management of tendinopathy. This study adds evidence to support the use of LR-PRP in gluteal tendinopathy.

The crossover (failed treatment) rate in the CSI group after 24 weeks made statistical comparison between groups difficult at 52 and 104 weeks, with only 15 patients remaining in the CSI group at 1 year and 11 at 2 years. This reflects the failure rate of the corticosteroid and was anticipated.

Having a crossover group allowed us to assess whether having a prior CSI may negatively or positively influence the outcome of the LR-PRP injection. Based on general linear model analysis, there was no relationship to previous number of CSIs and outcome scores in the CSI and LR-PRP groups. The crossover group (CSI + LR-PRP), which had a corticosteroid initially and then an LR-PRP injection at approximately 16 and 52 weeks, followed a similar pathway, with a mean

baseline score of 59.22 (SD, 11.54) as compared with the LR-PRP baseline of 53.77 (SD, 12.08). The scores showed no statistical difference at 24 weeks (CSI + LR-PRP, 77.69 [SD, 15.30]; LR-PRP, 77.60 [SD, 11.88]) or 52 weeks (CSI + LR-PRP, 79.04 [SD, 14.28]; LR-PRP, 78.18 [SD, 14.53]). This is reassuring for the clinician and implies that a previous CSI does not result in a poorer outcome for a patient who subsequently has an LR-PRP injection.

The strength of this study is the follow-up period of 2 years, which allowed us to see that the positive effect of the PRP had been sustained. The study controlled for the natural history of acute tendinopathy by inclusion of patients with a mean length of symptoms >14 months. The crossover permitted us to be confident of this, as there was no significant dropout rate (ie, the failed patients were captured by the crossover arm).

The limitations of this study are that comparisons among groups after 24 weeks are based on an open-labeled extension. Conclusions relating to the sustained outcome in the LR-PRP group, however, are not affected by this, as the patients remained blinded. The correlation between grade of tendinopathy and outcome has not been formally assessed. However, it is interesting to reflect that the LR-PRP group had twice the number of grade 3 tendinopathy patients as the CSI group. This could have led to a worse response rate; that it has not done so implies that at least up to grade 3 tendinopathy may be treated successfully with LR-PRP. The finding that there was progressive improvement up to 2 years, suggesting a somewhat prolonged recovery, has not been checked with radiological studies. Other authors looked at radiological changes earlier,^{9,16,20} but this finding suggests that these changes may be delayed, if they are present. Further study of imaging among these patients after 2 years may help to resolve whether there are longer-term structural changes.

CONCLUSION

Among patients with chronic gluteal tendinopathy and a length of symptoms >15 months, a single intratendinous LR-PRP injection performed under ultrasound guidance results in a greater improvement in pain and function than a single CSI. These results continue to improve out to 2 years.

ACKNOWLEDGMENT

The authors acknowledge the support of Sally Boyd for administration and coordination aspects of the clinical trial and Zimmer Biomet USA for the provision of the GPS III PRP separation kits used in this trial.

REFERENCES

1. Barnhouse NC, Wente TM, Voos JE. Greater trochanteric pain syndrome: endoscopic treatment options. *Oper Tech Sports Med.* 2012;20(4):320-324.
2. Behera P, Dhillon M, Aggarwal S, Marwaha N, Prakash M. Leukocyte-poor platelet-rich plasma versus bupivacaine for recalcitrant lateral epicondylar tendinopathy. *J Orthop Surg.* 2015;23(1):6-10.

3. Bhabra G, Wang A, Ebert JR, Edwards P, Zheng M, Zheng MH. Lateral elbow tendinopathy: development of a pathophysiology-based treatment algorithm. *Orthop J Sports Med.* 2016;4(11):2325967116670635.
4. Bird PA, Oakley SP, Shnier R, Kirkham BW. Prospective evaluation of magnetic resonance imaging and physical examination findings in patients with greater trochanteric pain syndrome. *Arthritis Rheum.* 2001;44(9):2138-2145.
5. Chahal J, Van Thiel GS, Mather RC 3rd, et al. The patient acceptable symptomatic state for the modified Harris Hip Score and Hip Outcome Score among patients undergoing surgical treatment for femoroacetabular impingement. *Am J Sports Med.* 2015;43(8):1844-1849.
6. Connell DA, Bass C, Sykes CA, Young D, Edwards E. Sonographic evaluation of gluteus medius and minimus tendinopathy. *Eur Radiol.* 2003;13(6):1339-1347.
7. Cook JL, Purdam CR. Is tendon pathology a continuum? A pathology model to explain the clinical presentation of load-induced tendinopathy. *Br J Sports Med.* 2009;43(6):409-416.
8. Craig RA, Jones DP, Oakley AP, Dunbar JD. Iliotibial band Z-lengthening for refractory trochanteric bursitis (greater trochanteric pain syndrome). *ANZ J Surg.* 2007;77(11):996-998.
9. de Jonge S, de Vos RJ, Weir A, et al. One-year follow-up of platelet-rich plasma treatment in chronic Achilles tendinopathy: a double-blind randomized placebo-controlled trial. *Am J Sports Med.* 2011;39(8):1623-1629.
10. Del Buono A, Papalia R, Khanduja V, Denaro V, Maffulli N. Management of the greater trochanteric pain syndrome: a systematic review. *Br Med Bull.* 2012;102:115-131.
11. Dragoo JL, Wasterlain AS, Braun HJ, Nead KT. Platelet-rich plasma as a treatment for patellar tendinopathy: a double-blind, randomized controlled trial. *Am J Sports Med.* 2014;42(3):610-618.
12. Fearon AM, Cook JL, Scarvell JM, Neeman T, Cormick W, Smith PN. Greater trochanteric pain syndrome negatively affects work, physical activity and quality of life: a case control study. *J Arthroplasty.* 2014;29(2):383-386.
13. Fitzpatrick J, Bulsara M, Zheng MH. The effectiveness of platelet-rich plasma in the treatment of tendinopathy: a meta-analysis of randomized controlled clinical trials. *Am J Sports Med.* 2017;45(1):226-233.
14. Fitzpatrick J, Bulsara MK, McCrory PR, Richardson MD, Zheng MH. Analysis of platelet-rich plasma extraction variations in platelet and blood components between 4 common commercial kits. *Orthop J Sports Med.* 2017;5(1):232596711667527.
15. Fitzpatrick J, Bulsara MK, O'Donnell J, McCrory PR, Zheng MH. The effectiveness of platelet-rich plasma injections in gluteal tendinopathy: a randomized, double-blind controlled trial comparing a single platelet-rich plasma injection with a single corticosteroid injection. *Am J Sports Med.* 2018;46(4):933-939.
16. Gautam VK, Verma S, Batra S, Bhatnagar N, Arora S. Platelet-rich plasma versus corticosteroid injection for recalcitrant lateral epicondylitis: clinical and ultrasonographic evaluation. *J Orthop Surg (Hong Kong).* 2015;23(1):1-5.
17. Gosens T, Peerbooms JC, van Laar W, den Ouden BL. Ongoing positive effect of platelet-rich plasma versus corticosteroid injection in lateral epicondylitis: a double-blind randomized controlled trial with 2-year follow-up. *Am J Sports Med.* 2011;39(6):1200-1208.
18. Kingzett-Taylor A, Tirman PF, Feller J, et al. Tendinosis and tears of gluteus medius and minimus muscles as a cause of hip pain: MR imaging findings. *AJR Am J Roentgenol.* 1999;173(4):1123-1126.
19. Kong A, Van der Vliet A, Zadow S. MRI and US of gluteal tendinopathy in greater trochanteric pain syndrome. *Eur Radiol.* 2007;17(7):1772-1783.
20. Krogh TP, Fredberg U, Stengaard-Pedersen K, Christensen R, Jensen P, Ellingsen T. Treatment of lateral epicondylitis with platelet-rich plasma, glucocorticoid, or saline: a randomized, double-blind, placebo-controlled trial. *Am J Sports Med.* 2013;41(3):625-635.
21. Kvien TK, Heiberg T, Hagen KB. Minimal clinically important improvement/difference (MCII/MCID) and patient acceptable symptom state (PASS): what do these concepts mean? *Ann Rheum Dis.* 2007;66(suppl 3):iii40-iii41.
22. Labrosse JM, Cardinal E, Leduc BE, et al. Effectiveness of ultrasound-guided corticosteroid injection for the treatment of gluteus medius tendinopathy. *AJR Am J Roentgenol.* 2010;194(1):202-206.
23. Lievens A, Bierma-Zeinstra S, Schouten B, Bohnen A, Verhaar J, Koes B. Prognosis of trochanteric pain in primary care. *Br J Gen Pract.* 2005;55(512):199-204.
24. Lustenberger DP, Ng VY, Best TM, Ellis TJ. Efficacy of treatment of trochanteric bursitis: a systematic review. *Clin J Sport Med.* 2011;21(5):447-453.
25. Mishra AK, Skrepnik NV, Edwards SG, et al. Efficacy of platelet-rich plasma for chronic tennis elbow: a double-blind, prospective, multicenter, randomized controlled trial of 230 patients. *Am J Sports Med.* 2014;42(2):463-471.
26. Moraes VY, Lenza M, Tamaoki MJ, Faloppa F, Bellotti JC. Platelet-rich therapies for musculoskeletal soft tissue injuries. *Cochrane Database Syst Rev.* 2014;4:CD010071.
27. Murray IR, Geeslin AG, Goudie EB, Petrigliano FA, LaPrade RF. Minimum information for studies evaluating biologics in orthopaedics (MIBO): platelet-rich plasma and mesenchymal stem cells. *J Bone Joint Surg Am.* 2017;99(10):809-819.
28. Rasmussen Ege KJ, Fanø N. Trochanteric bursitis treatment by corticosteroid injection. *Scand J Rheumatol.* 1985;14:417-420.
29. Rha DW, Park GY, Kim YK, Kim MT, Lee SC. Comparison of the therapeutic effects of ultrasound-guided platelet-rich plasma injection and dry needling in rotator cuff disease: a randomized controlled trial. *Clin Rehabil.* 2013;27(2):113-122.
30. Rompe JD, Segal NA, Cacchio A, Furia JP, Morral A, Maffulli N. Home training, local corticosteroid injection, or radial shock wave therapy for greater trochanter pain syndrome. *Am J Sports Med.* 2009;37(10):1981-1990.
31. Shbeeb MI, O'Duffy JD, Michet CJ Jr, O'Fallon WM, Matteson EL. Evaluation of glucocorticosteroid injection for the treatment of trochanteric bursitis. *J Rheumatol.* 1996;23(12):2104-2106.
32. Slawski DP, Howard RF. Surgical management of refractory trochanteric bursitis. *Am J Sports Med.* 1997;25(1):86-89.
33. Verhelst L, Guevara V, De Schepper J, Van Melkebeek J, Pattyn C, Audenaert EA. Extra-articular hip endoscopy: a review of the literature. *Bone Joint Res.* 2012;1(12):324-332.
34. Vetrano M, Castorina A, Vulpiani MC, Baldini R, Pavan A, Ferretti A. Platelet-rich plasma versus focused shock waves in the treatment of jumper's knee in athletes. *Am J Sports Med.* 2013;41(4):795-803.
35. Walsh MJ, Walton JR, Walsh NA. Surgical repair of the gluteal tendons: a report of 72 cases. *J Arthroplasty.* 2011;26(8):1514-1519.
36. Williams BS, Cohen SP. Greater trochanteric pain syndrome: a review of anatomy, diagnosis and treatment. *Anesth Analg.* 2009;108(5):1662-1670.